Special Care Dentistry

Editor

BURTON S. WASSERMAN

DENTAL CLINICS OF NORTH AMERICA

www.dental.theclinics.com

July 2016 • Volume 60 • Number 3

Treatment of Orally Handicapped Edentulous Older Adults Using Dental Implants

Charles Zahedi, DDS, PhD

KEYWORDS

• Edentulism • Tooth loss • Dental implants • Mini–dental implants • Osseointegration • Prosthodontics • Overdentures

KEY POINTS

- The oral handicap of complete edentulism is the terminal outcome of a multifactorial process involving biological factors and patient-related factors. It will continue to represent a very large global health care burden for the foreseeable future.
- The fully edentulous orally handicapped older adult population has been neglected because removable acrylic dentures have been the classic therapy for complete edentulism. These soft tissue–supported prostheses do not treat alveolar bone loss or prevent disuse atrophy or pressure-mediated resorption, which are all germane to edentulism. Therefore, they are only rehabilitative, not therapeutic.
- Not replacing missing teeth with stable dentures could prevent adequate food intake.
- To address the oral handicap of complete edentulism, osseointegrated endosseous implants could be used as a therapeutic adjunct and could reduce the problem of long-term bone resorption to less than 0.1 mm per year.
- Implant-borne prostheses substantially improve the overall health and quality of life of orally handicapped fully edentulous older adults.

INTRODUCTION

The older adult population (defined as those aged 65 years and older) is the fastest growing age group in American society. The US Bureau of the Census reported that in 2010 there were more than 40 million older Americans representing nearly 13% of the population. The Census Bureau projects that more than 20% of American adults

Disclosure: All patients in this article were treated by Dr C. Zahedi and all radiographic and clinical material were provided by Dr C. Zahedi. Dr C. Zahedi is a consultant for Mobile Dental USA.

Department of Periodontics, University of California, Los Angeles (UCLA), Implant Mentoring/Implant Outreach Institute, 4221 MacArthur Blvd, Newport Beach, CA 92660, USA
E-mail address: info@implantmentoring.com

Dent Clin N Am 60 (2016) 663–691
http://dx.doi.org/10.1016/j.cden.2016.02.007 **dental.theclinics.com**
0011-8532/16/$ – see front matter

will be aged 65 years or older by the year 2040. The increase in the elderly population has affected the oldest groups the most. For instance, from the beginning of the twentieth century to the present, there has been an 800% increase in the size of the 65-year-old to 74-year-old age group, but the number of Americans aged 85 years and older has increased by 2500% over the same period.[1–3]

The aging population is bringing with it an increase in the number of teeth lost. As a result, the population in need of treatment of complete edentulism is larger than ever.[4]

Oral handicap of complete edentulism can be defined as the physical state of the jaws following removal of all erupted teeth and the condition of the supporting structures available for reconstructive or replacement therapies. It is the terminal outcome of a multifactorial process involving biological factors and patient-related factors. It represents a huge global health care burden and will continue to do so for the foreseeable future.

The fully edentulous orally handicapped older adult population has been neglected because removable acrylic dentures have been the classic therapy for complete edentulism. These soft tissue–supported prostheses do not treat alveolar bone loss or prevent disuse atrophy or pressure-mediated resorption, which are all germane to edentulism. Therefore, they are only rehabilitative, not therapeutic.[5,6]

To address the oral handicap of complete edentulism, osseointegrated endosseous implants should be used as a therapeutic adjunct. Implants can reduce the problem of long-term bone resorption to less than 0.1 mm per year while providing adequate masticatory function.[7]

However, most denture wearers are not aware that the pressure of their removable dentures on the jaw results in the loss of the jaw bone, thus reducing the stability of their dentures. It can be frustrating to eat certain foods or to try to speak with confidence with the fear that the denture will begin to float in the mouth. Not replacing missing teeth with stable dentures prevents adequate food intake, resulting in a lack of proper nutrients and vitamins and leading to weight loss and serious medical conditions such as heart disease and poor cognitive function.[7–9]A low number of teeth increases the risk of higher prevalence and incidence of dementia.[10]

To address the disease of edentulism, endosseous implants are being used as a therapeutic adjunct and can reduce the problem of long-term bone resorption to less than 0.1 mm per year. Dental implants offer many advantages in the oral rehabilitation of older patients.[11] The use of dental implants for support and/or retention of fixed or removable prostheses has been shown to be an important opportunity to enhance prosthodontic treatment outcomes and quality of life for patients with complete edentulism.[12]

This article reviews and discusses the current techniques to rehabilitate fully edentulous older adult patients by means of dental implants.

OSSEOINTEGRATION

Osseointegration of the implants to the bone is one the most crucial factors that influences the long-term predictability of the implant placement procedure. Osseointegration, defined as a direct structural and functional connection between ordered, living bone and the surface of a load-carrying implant, is critical for implant stability, and is considered a prerequisite for implant loading and long-term clinical success of endosseous dental implants.[13] Osseointegration involves an initial interlocking between alveolar bone and the implant body, and, later, biological fixation through continuous bone apposition and remodeling toward the implant. It is a complex process in which

many factors influence the formation and maintenance of bone at the implant surface.[14]

Indications for Dental Implants for Older Adults

There are a myriad of treatment options and related investment (costs) for completely edentulous patients. They range from overdentures supported by only 2 implants to full-arch fixed partial dentures (implant bridges) supported by 4 or more implants.

The indications for dental implants in older adults are in general not different from the rest of the population because chronologic age is not a contraindication for dental implants. It has also been reported that older individuals respond to oral implants in the same manner as younger adults, despite their tendency for systemic illness.[12]

In a comparison of 2 closely matched groups of completely edentulous younger and older patients with dental implants after follow-up times of 4 to 16 years, a cumulative success rate of 92% in the older group and 86.5% in the younger group were reported.[15] Even more importantly, the prosthesis success rate was 100%, and the original prosthesis was in place throughout the respective observation periods for 41 of 45 of the older patients. The remaining prostheses needed repair at some point in the follow-up.[15]

The mental state of edentulous patients can be improved with overdentures and the enhancement can be caused by functional improvement with prostheses when loaded with implants and not by the mere existence of implants without any function.[16]

Precautions for Medically Compromised Patients

Medically compromised patients are defined as patients with decreased or compromised physical and mental ability to perform regular tasks compared with normal people of same age.[17]

Cardiac systemic diseases

Implants in patients with cardiac systemic diseases may show lower levels of osseointegration caused by compromised oxygen and nutrient supply in the bone. These patients may also be at a higher risk of developing infective endocarditis.[18–20] Dentists should take the opinion of the primary physicians of the patients about whether the condition is medically controlled or not.

Radiotherapy

Radiotherapy is not considered a major risk factor for implant loss. However, it might lead to implant loss or negatively affect osseointegration if it is administered over the oral cavity, involves ionizing radiation, or the radiation dose is higher than 50 Gy.[17]

Tobacco

Consumption of tobacco has been significantly associated with implant loss. The implant failure rate is 2.5 to 2.6 times higher in patients who smoke compared with nonsmokers.[21–23]

Diabetes

In the past, type II diabetes was considered an absolute contraindication because of risk of infection and failure of osseointegration, but more recent studies[24,25] have shown that the implant failure rate is much lower if the condition is controlled. The surgery needs to be done using aseptic techniques accompanied by an appropriate antibiotic regimen.

Osteoporosis

Osteoporosis has been considered as a risk factor for implant failure because of the bone loss that occurs in this condition, but most recent studies[23,26–28] have concluded that it should not be considered as a contraindication for implant placement. However, if the patient is taking oral bisphosphonates, the condition should be treated as a relative or partial contraindication. It is an absolute contraindication if bisphosphonates are being delivered intravenously or there is an associated corticosteroid, immune-suppressor, or hormonal therapy regimen.

In conclusion, systemic conditions do not affect implant survival if they are controlled,[29] but this needs to be confirmed with randomized controlled trials. It is more important for the disease to be in a controlled condition than the disease itself and, to determine the appropriate course of action, a proper medical examination needs to be done.[30]

SIMPLIFICATION AND RATIONALIZATION

Several rules, often considered as dogmas, made it possible for oral implants to achieve a high success rate. However, some of these concepts have been questioned. The submerged nature of implant placement, the arbitrary 3-month to 6-month healing period, bicortical anchorage, placement of the longest possible implants, as well as implant placement in strict sterile conditions have been scientifically challenged. An in-depth knowledge and experience in both the surgical and prosthetic aspects of oral implantology are of utmost importance in order to achieve a high success rate.[31]

Types of Dental Implants

There are 3 types of implants, and they can be described according to their shape and how they are attached to the jaw (**Fig. 1**):

1. Endosseous implants are usually shaped like a screw or cylinder and are placed within the jawbone. There are also blade-shaped endosseous implants. Osseointegrated endosseous dental implants have provided successful and predictable long-term results.[32]
2. Subperiosteal implants consist of a metal framework that attaches on top of the jawbone but underneath the gum tissue (**Fig. 2**).
3. Transosteal implants are either a metal pin or a U-shaped frame that passes through the jawbone and the gum tissue, into the mouth.

Fig. 1. Panoramic radiograph of an older adult showing on the upper left a subperiosteal implant and on the lower right a blade implant. There are also 2 endosseous screw-type implants on the maxillary anterior.

Fig. 2. Patient was complaining for more than 2 years of bad smell and taste in his mouth. The removed subperiosteal implant is shown, along with an endosseous implant after removal of the bridge. Huge amounts of plaque and food debris have accumulated under the bridge.

Bone Regeneration Before or Immediately after Implant Placement

Bone volume (quantity) and density (quality) are the main prerequisites for safe and predictable implant placement and for attaining the functional stability of the implant needed to achieve osseointegration.

The bone morphology at the osteotomy site influences the ideal implant position at placement. Any deficiency in horizontal and vertical dimensions might require bone augmentation procedures.

Animal studies have also shown that guided bone regeneration using membranes is successful to regenerate bone by protecting the blood clot from the surrounding soft tissue.[33–35] Animal studies have shown that bone grafting around implants at insertion is feasible and histologically documented.[36]

Clinically, various bone substitutes for bone grafting have been used successfully in several indications and histologic and clinical outcomes reported in different oral bone regenerative procedures, such as socket preservation, immediate implant placement,[37] sinus grafting, and lateral and vertical bone augmentation.

Each biomaterial has advantages and disadvantages that are discussed in various reviews.[38,39]

FACTORS AFFECTING IMPLANT LOSS

The stabilization of the lower denture with at least 2 endosseous implants has been used for more than 20 years and was already recommended in the McGill consensus statement as standard therapy in 2002.[40,41]

A recent systematic review of factors associated with postloading implant loss in implant-supported prostheses in edentulous jaws analyzed the potential impact of implant location (maxilla vs mandible), implant number per patient, type of prosthesis (removable vs fixed), and type of attachment system (screw retained, ball vs telescopic crown) on implant loss.[42]

The 5-year survival rate of implants was about 98% and it was slightly higher in mandible than maxilla. In contrast, implant loss rate was significantly higher ($P = .05$) in maxilla compared with mandible.

Loss of implants was greater with removable prostheses than with fixed restorations ($P<.05$). The lower the number of implants, the higher the implant loss rate with fixed restorations.[42] Similar results were found with overdentures: the lower the number of implants, the higher the implant loss rate with maxillary and mandibular overdentures. The investigators concluded that the implant location and the number and type of prostheses affect the implant rate. Hence, during treatment planning, the number of implants should be decided by taking into account the type of the prosthesis preferred by the patient and the location of the implants:

RECOMMENDATIONS

Maxilla:

- For removable overdentures: 4 or more implants provide favorable results (see **Fig. 1** and **2**; **Figs. 3–21**)
- For fixed prostheses: 6 or more implants provide good results (**Figs. 22–25**).

Mandible:

- For removable overdentures: 2 or more implants provide favorable results (**Figs. 26–44**)
- Four implants with removable prostheses showed more favorable results than the same number of implants with fixed prosthesis
- For fixed prostheses: 4 or more implants provide good results

Reduced-diameter Implants

A systemic review of the success of narrow-diameter dental implants concluded that narrow-diameter implants of 3.3 to 3.5 mm are well documented in all indications including load-bearing posterior regions. Smaller implants of 3.0 to 3.25 mm in diameter are well documented only for single-tooth non–load-bearing regions. Mini-implants less than 3.0 mm in diameter are only documented for the edentulous arch and single-tooth non–load-bearing regions[43] (**Figs. 45** and **46**).

Mini–dental implants can provide immediate stabilization of a dental prosthetic appliance after a minimally invasive procedure. Furthermore, mini-implants can

Fig. 3. The removed blade implant from the lower jaw.

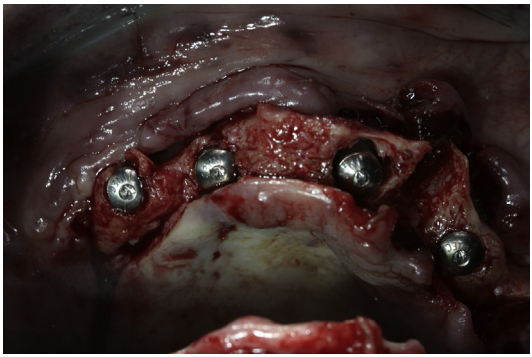

Fig. 4. Four osseointegrated endosseous dental implants inserted in the maxilla.

Fig. 5. Bone grafting was necessary because of insufficient bone volume and to preserve the bone volume at the extraction site.

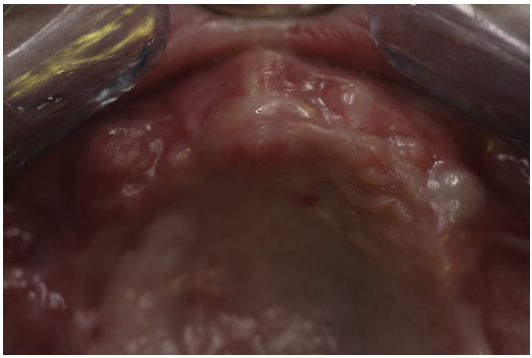

Fig. 6. Soft tissue healing following the placement of implants and bone grafts.

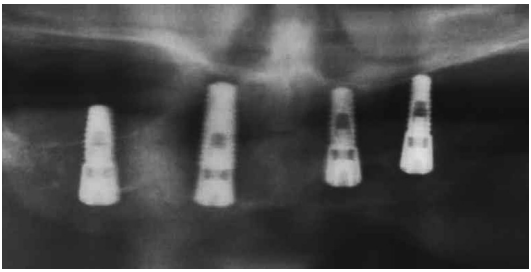

Fig. 7. Panoramic radiographic view following the placement of 4 endosseous osseointegrated implants.

Fig. 8. Soft tissue healing 3 weeks after the second-phase surgery and exposing the implants to the oral cavity.

Fig. 9. Impression copings used for final impression.

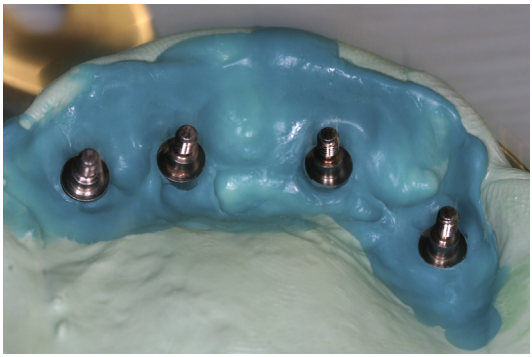

Fig. 10. Impression copings in the final impression.

Fig. 11. Implant analogs attached to the impression copings.

Fig. 12. Cast bar being prepared on the model.

Fig. 13. The overdenture with attachments.

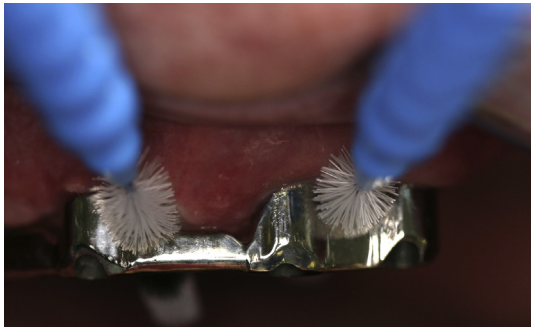

Fig. 14. The patient is instructed on the proper oral hygiene/plaque control methods using appropriate-sized interdental brushes.

Fig. 15. The patient is wearing the final overdenture.

Fig. 16. Six maxillary implants on a fully edentulous older adult patient.

Fig. 17. Occlusal view of the maxillary implants.

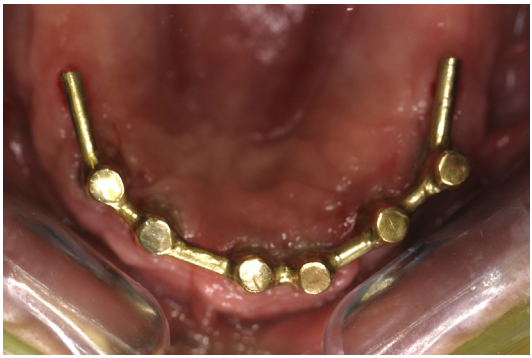

Fig. 18. Cast bar with distal extensions.



Fig. 19. Attachment connecting the overdenture to the cast bar.

Fig. 20. Cast bar in the overdenture before final connection to the maxillary implants.

Fig. 21. Final maxillary overdenture.

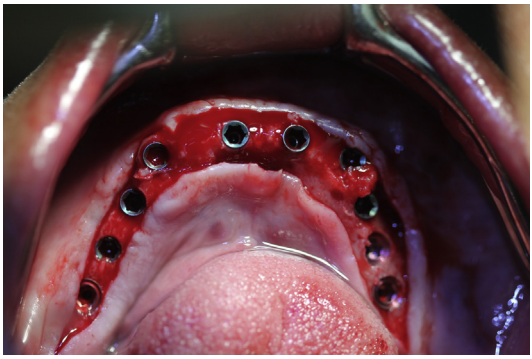

Fig. 22. Intrasurgical occlusal view showing the placement of osseointegrated implants on the mandible for a fixed partial denture (implant bridge).

Fig. 23. Occlusal view of the healed soft tissue around the prosthetic abutments.

Fig. 24. Occlusal view of the zirconia bridge.

Fig. 25. This older adult has been instructed to use interproximal brushes for optimal plaque control.

be used in cases in which traditional implants are impractical, or when a different type of anchorage system is needed. Healing time required for mini-implant placement is typically shorter than that associated with conventional 2-stage implant placement and the accompanying extensive surgical procedure.

Overdentures retained by 2 to 4 mini-implants can achieve oral health–related quality of life and satisfaction at least comparable with that of 2 standard implants. However, the survival rate of mini-implants is not as high as that of standard implants.[44]

The design of mini-implants is such that insertion techniques minimize peri-implant tissue and bone damage. Because of their versatility and ease of insertion, mini-implants have proved useful as transitional stabilizers and as fixtures for long-term prosthesis function.



Fig. 26. Only one drill, 1.1 mm in diameter, could be used to prepare the osteotomy site to place mini–dental implants.

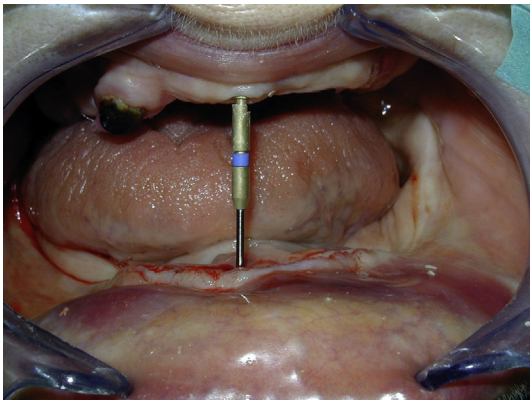

Fig. 27. To place mini-implants, first, a drill is used to locate the midline and the proper mesiodistal and buccolingual direction of insertion. However, in most cases, no mini-implants are placed on the midline. This first drill is only used as a direction indicator.

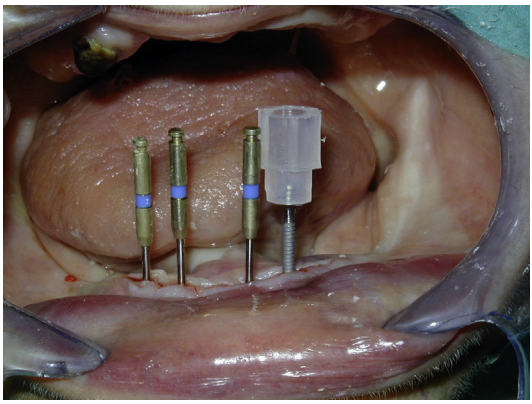

Fig. 28. Once all osteotomy sites are ready, mini-implants are inserted manually.

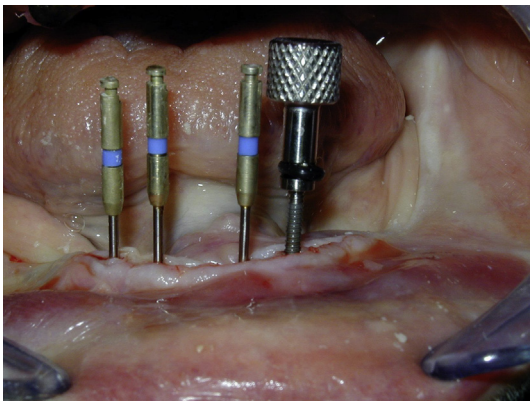

Fig. 29. With increased resistance to placement, a finger driver is used.

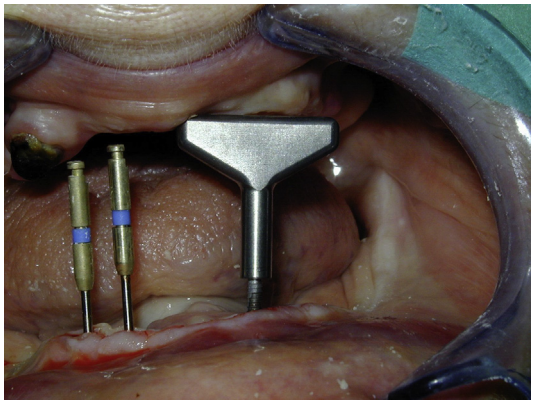

Fig. 30. The finger driver is followed by a winged thumb wrench until the wrench becomes difficult to turn.

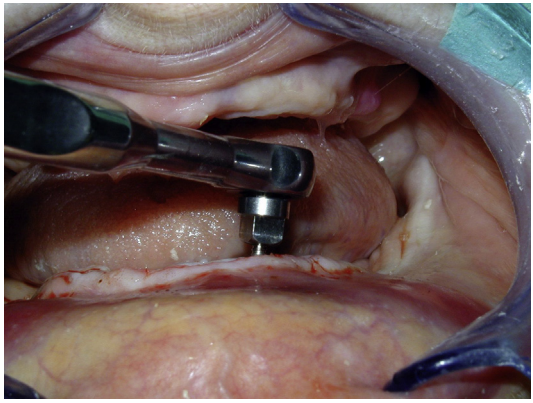

Fig. 31. A ratchet wrench or an adjustable torque wrench then finalizes the insertion process.

Fig. 32. Buccal view of mini-implants after 3 weeks of soft tissue healing.

Fig. 33. Occlusal view after soft tissue healing showing a sufficient band of attached keratinized mucosa around all 4 mini–dental implants.

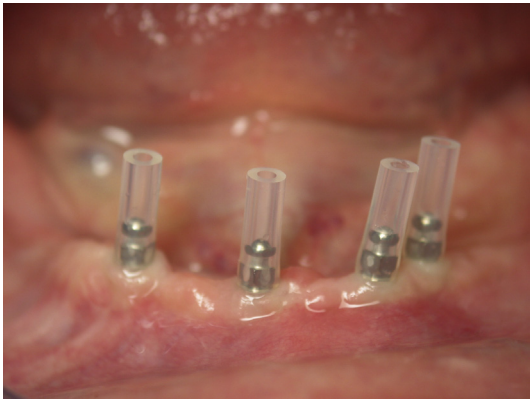

Fig. 34. Blockout shims placed over mini–dental implants to prevent the interlocking of hard acrylic resin after polymerization.

Fig. 35. Blockout shims cut to the proper height.

Fig. 36. Metal housings are attached to the implants. Blockout shims are verified individually.



Fig. 37. Relieve the intaglio surface of the denture base at least 1 mm around the metal housings to prevent overload on any single mini-implant.

Fig. 38. Sufficient space is created on the intaglio surface of the overdenture to accommodate the metal housings.

Fig. 39. Metal housings including the O-rings are now connected to the overdenture using acrylic resin.

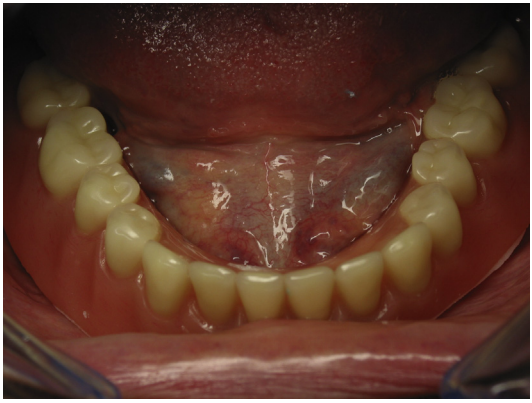

Fig. 40. The final overdenture is now sitting on the mini-implants.

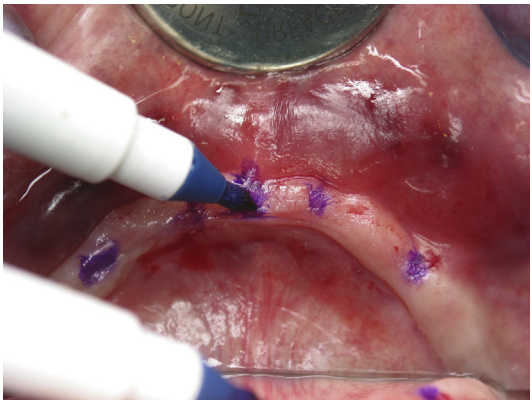

Fig. 41. Using markers on the mucosa for more precise insertion of the drills.

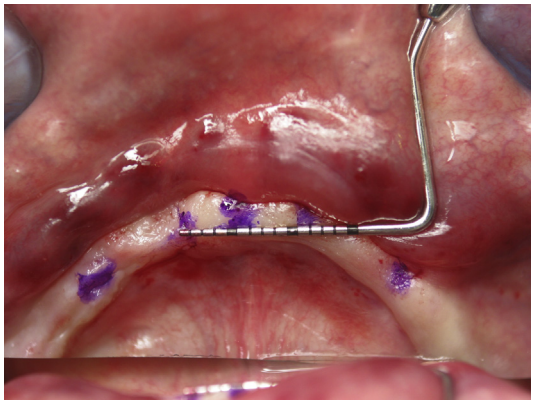

Fig. 42. Measurement of interimplant distances using a 15-mm periodontal proble.

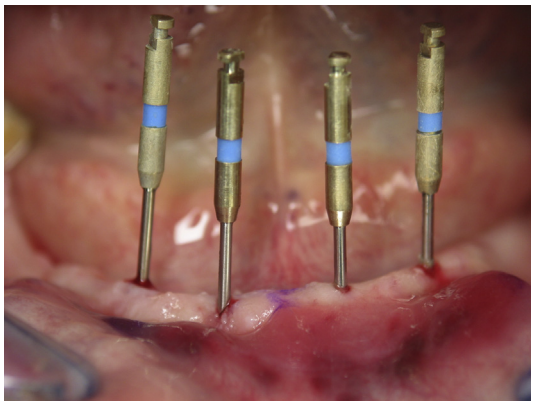

Fig. 43. Guide drills already inserted to ensure interimplant distances and parallelism.

Fig. 44. Mini-implants placed on the anterior mandible using a flapless approach.

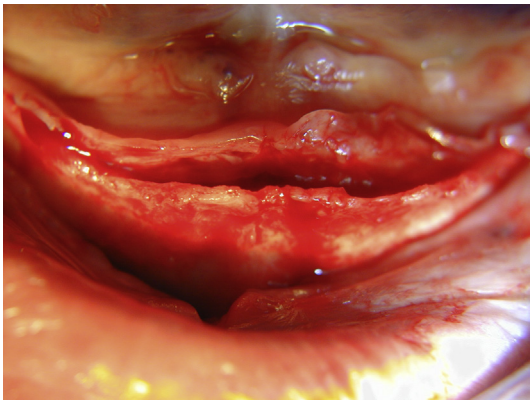

Fig. 45. Very thin ridge on the mandible precluding the placement of regular-diameter implants.

A biometric analysis of 1029 mini dental implant, 5 months to 8 years in vivo, representing 5 clinics, showed a failure rate for stabilization on average of 8.83%, showing fairly consistent long-term prosthesis stabilization and implant success.[45]

Mobile Dental USA specializes in treating older adults in nursing homes and assisted living communities (www.mobiledentalusa.com), and offers a solution called the Bone-loss and Denture-loss Prevention Program™. This solution includes the use of regular-diameter implants but also mini–dental implants. When using mini–dental implants, the Bone-loss and Denture-loss Prevention Program™ offers several advantages:

- Eliminates the life-threatening risk of residents swallowing their removable dentures.
- Improved overall health and increased life expectancy by enabling residents to eat using stable dentures without the need for denture adhesives.



Fig. 46. Difference in diameter between the osteotomy site for a regular-sized (*left*) versus a mini–dental implant (*right*).

- Residents can immediately start eating and speak with confidence.
- Reduced healing time: this is a 1-step procedure that can be done in 1 hour and requires no sutures or the typical months of healing.
- Residents with memory loss (Alzheimer, dementia) will never lose their dentures again and could continuously wear dentures even while sleeping.
- The ongoing loss of the jaw bone stops at the implant sites.
- The more the residents bite on the MDIs, the more they stimulate their jaw bones.
- It is impossible to have any cavities or root canal problems on MDIs.
- It is a solution for residents who cannot have extensive surgery for medical reasons.
- Eliminates the cost of replacing lost removable dentures, especially for memory-impaired adults.
- This therapeutic solution is affordable compared with traditional implant solutions.

Preparation

For fully edentulous older adults, the adequacy of existing removable prostheses has to be assessed in terms of their stability, function, esthetics, and material integrity. In most cases, existing dentures are not satisfactory and a new set has to be made to correctly determine the vertical dimension of occlusion, interarch relationship, and tooth positioning for optimal esthetic, phonetic, and functional effects.

The diagnostic denture setup aids clinicians to a great extent with the assessment if a fixed implant–borne prosthesis is feasible or if a removable approach promises to be more favorable.

The use of volumetric imaging, such as cone beam computed tomography (CBCT), is emerging as a valued aid in planning, placement, and restoration of dental implants.

Radiographic guides could simply be made out of the existing dentures (**Figs. 47** and **48**). These guides could then be used as surgical guides (**Fig. 49**). More sophisticated, but also costly, surgical guides could be made by using

Fig. 47. The existing dentures of the patient can be transformed into radiological and surgical guides.

Fig. 48. Radiological guide that will be transformed to a surgical guide after the radiographs (CBCT scans) have been made.

Fig. 49. Surgical guide made by transforming the radiological guide.

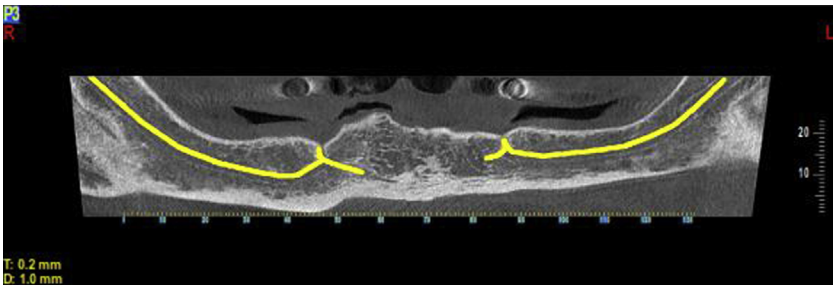

Fig. 50. Two-dimensional (panoramic) view from a CBCT scan on a fully edentulous mandible showing the simulation of the location of the inferior alveolar nerve in yellow.

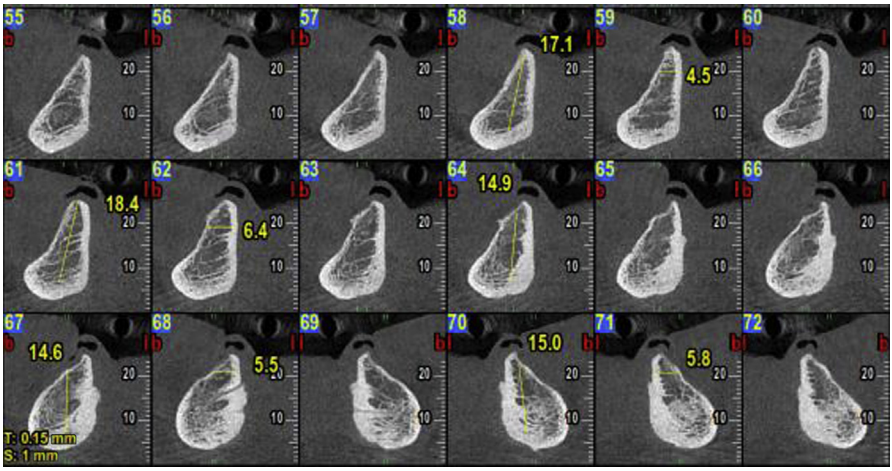

Fig. 51. Cross-sectional images from the CBCT on a fully edentulous mandible.

appropriate software tools that offer three-dimensional control of implant placement.[46]

When using CBCT, clinicians should take into consideration the effective doses for different devices because they have a wide range, with the lowest dose being almost 100 times less than the highest dose.[47] Significant dose reduction can be achieved by adjusting operating parameters, including exposure factors and reducing the field of view to the region of interest[47] (**Figs. 50–52**).

Maintenance

Older adults who have been provided with dental implants should be educated and trained to control plaque biofilm associated with peri-implant tissues and associated restorations.

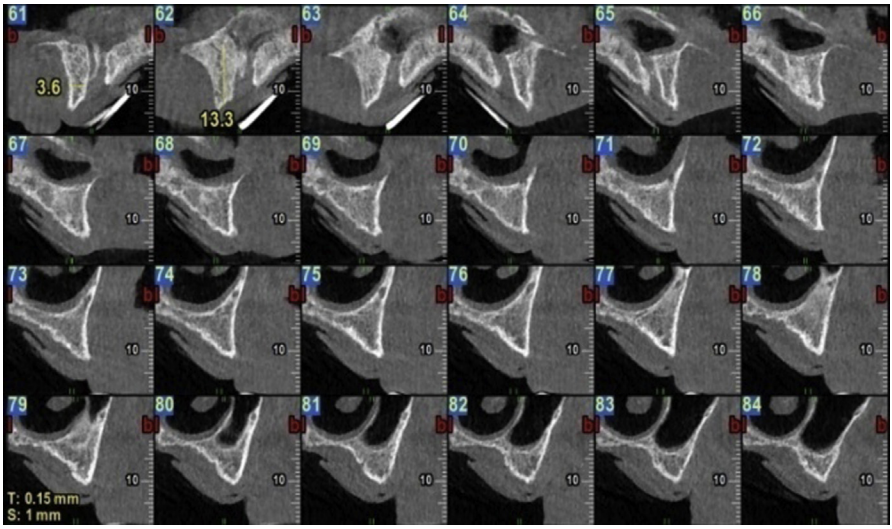

Fig. 52. Cross-sectional images obtained from CBCT showing the limited bone volume in the maxilla.

Fig. 53. Insufficient plaque control leading to peri-implant mucositis and peri-implantitis.

There are differences between peri-implant interface and natural teeth that influence the maintenance of soft tissues around implants. The peri-implant soft tissue interface has been shown to be less effective than natural teeth in resisting bacterial invasion. Gingival fiber alignment and reduced vascular supply make the peri-implant soft tissue more vulnerable to subsequent peri-implant disease, such as peri-implant mucositis and peri-implantitis, leading to bone loss around implants.[48] (Fig. 53).

Older adult patients with implants should be recalled every 2 to 6 months for examination and professional cleaning. At each visit, ensure that the patient is able to perform optimal plaque removal around the dental implants. Peri-implant tissues should be examined for signs of inflammation and bleeding on probing and/or suppuration and remove supramucosal and submucosal plaque and calculus deposits and excess residual cement. Perform radiographic examination only when clinically indicated.[49]

Implants are probed, examined for stability/mobility, and sites inspected for local disorder (plaque, calculus, bleeding, suppuration) and need for treatment. Assessment of peri-implant mucositis (mucosal inflammation) is primarily made by observing bleeding following light probing (0.25 N) of the implant sulcus/pocket. The absence of bleeding on probing has a high negative predictive value, providing the clinician a predictor of stable peri-implant conditions (Figs. 54 and 55).

If inflammation or infection is detected clinically, diagnostic radiographs are obtained as well. Implants become mobile only when advanced bone loss or occlusal

Fig. 54. Interdental brushes are easy to use by older adults.

Fig. 55. Special toothbrushes are used around mini-implants.

overload have resulted in the loss of osseointegration. Therefore, the early signs of peri-implant mucositis and peri-implantitis should be diagnosed to provide early treatment.

Implants are in general not instrumented with curettes except for the careful removal of mineralized deposits with special nonmetal curettes, followed by polishing with a nonabrasive or minimally abrasive polishing paste and rubber cup.[50]

REFERENCES

1. He W, Muenchrath MN. 90+ in the United States: 2006–2008 American Community Survey Reports. US Department of Health and Human Services ACS-17. 2011.
2. Doundoulakis JH, Eckert SE, Lindquist CC, et al. The implant-supported overdenture as an alternative to the complete mandibular denture. J Am Dent Assoc 2003;134(11):1455–8.
3. Douglass CW, Shih A, Ostry L. Will there be a need for complete dentures in the United States in 2020? J Prosthet Dent 2002;87(1):5–8.
4. Vos T, Flaxman AD, Naghavi M, et al. Years lived with disability (YLDs) for 1160 sequelae of 289 diseases and injuries 1990-2010: a systematic analysis for the Global Burden of Disease Study 2010. Lancet 2013;380(9859):2163–96.
5. Tallgren A. The continuing reduction of the residual alveolar ridges in complete denture wearers: a mixed-longitudinal study covering 25 years. J Prosthet Dent 1972;27(2):120–32.
6. White GS. Treatment of the edentulous patient. Oral Maxillofac Surg Clin North Am 2015;27(2):265–72.
7. Adell R, Lekholm U, Rockler B, et al. A 15-year study of osseointegrated implants in the treatment of the edentulous jaw. Int J Oral Surg 1981;10(6):387–416.
8. Okamoto N, Morikawa M, Tomioka K, et al. Association between tooth loss and the development of mild memory impairment in the elderly: the Fujiwara-kyo Study. J Alzheimers Dis 2015;44(3):777–86.
9. Liljestrand JM, Havulinna AS, Paju S, et al. Missing teeth predict incident cardiovascular events, diabetes, and death. J Dent Res 2015;94(8):1055–62.
10. Stein PS, Desrosiers M, Donegan SJ, et al. Tooth loss, dementia and neuropathology in the Nun study. J Am Dent Assoc 2007;138(10):1314–22.

11. Feine JS, Carlsson GE. Implant overdentures. The standard of care for edentulous patients. Chicago: Quintessence Publishing; 2003.
12. Bryant SR, Zarb GA. Outcomes of implant prosthodontic treatment in older adults. J Can Dent Assoc 2002;68(2):97–102.
13. Zarb CA, Albrektsson T. Nature of implant attachments. In: Branemark P-I, Zarb C, Albrektsson T, editors. Tissue-integrated prostheses osseointegration in clinical dentistry. Chicago: Quintessence Publishing; 1985. p. 88–98.
14. Albrektsson T, Brånemark PI, Hansson HA, et al. Osseointegrated titanium implants. Requirements for ensuring a long-lasting, direct bone-to-implant anchorage in man. Acta Orthop Scand 1981;52(2):155–70.
15. Bryant SR, Zarb GA. Osseointegration of oral implants in older and younger adults. Int J Oral Maxillofac Implants 1998;13(4):492–9.
16. Banu RF, Veeravalli PT, Kumar VA. Comparative evaluation of changes in brain activity and cognitive function of edentulous patients, with dentures and two-implant supported mandibular overdenture-pilot study. Clin Implant Dent Relat Res 2015. [Epub ahead of print]. http://dx.doi.org/10.1111/cid.12336.
17. Gómez-de Diego R, Mang-de la Rosa M, Romero-Pérez MJ, et al. Indications and contraindications of dental implants in medically compromised patients: update. Med Oral Patol Oral Cir Bucal 2014;19(5):e483–9.
18. Bornstein MM, Cionca N, Mombelli A. Systemic conditions and treatments as risks for implant therapy. Int J Oral Maxillofac Implants 2009;24(Suppl):12–27.
19. Hwang D, Wang HL. Medical contraindications to implant therapy: part II: relative contraindications. Implant Dent 2007;16(1):13–23.
20. Khadivi V, Anderson J, Zarb GA. Cardiovascular disease and treatment outcomes with osseointegration surgery. J Prosthet Dent 1999;81(5):533–6.
21. Wilson TG Jr, Nunn M. The relationship between the interleukin-1 periodontal genotype and implant loss. Initial data. J Periodontol 1999;70(7):724–9.
22. Susarla SM, Chuang SK, Dodson TB. Delayed versus immediate loading of implants: survival analysis and risk factors for dental implant failure. J Oral Maxillofac Surg 2008;66(2):251–5.
23. Holahan CM, Koka S, Kennel KA, et al. Effect of osteoporotic status on the survival of titanium dental implants. Int J Oral Maxillofac Implants 2008;23(5):905–10.
24. Beikler T, Flemmig TF. Implants in the medically compromised patient. Crit Rev Oral Biol Med 2003;14(4):305–16.
25. Morris HF, Ochi S, Winkler S. Implant survival in patients with type 2 diabetes: placement to 36 months. Ann Periodontol 2000;5(1):157–65.
26. Lee JY, Park HJ, Kim JE, et al. A 5-year retrospective clinical study of the Dentium implants. J Adv Prosthodont 2011;3(4):229–35.
27. de Melo L, Piattelli A, Lezzi G, et al. Human histologic evaluation of a six-year-old threaded implant retrieved from a subject with osteoporosis. J Contemp Dent Pract 2008;9(3):99–105.
28. Shibli JA, Aguiar KC, Melo L, et al. Histological comparison between implants retrieved from patients with and without osteoporosis. Int J Oral Maxillofac Surg 2008;37(4):321–7.
29. Lee HJ, Kim YK, Park JY, et al. Short-term clinical retrospective study of implants in geriatric patients older than 70 years. Oral Surg Oral Med Oral Pathol Oral Radiol Endod 2010;110(4):442–6.
30. Diz P, Scully C, Sanz M. Dental implants in the medically compromised patient. J Dent 2013;41(3):195–206.

31. Zahedi CS, Cassin D, Brunel G, et al. Simplification and rationalization of oral implantology. Rev Belge Med Dent 2001;56(1):62–71.
32. Adell R, Eriksson B, Lekholm U, et al. Long-term follow-up study of osseointegrated implants in the treatment of totally edentulous jaws. Int J Oral Maxillofac Implants 1990;5(4):347–59.
33. Zahedi S, Legrand R, Brunel G, et al. Evaluation of a diphenylphosphorylazide-crosslinked collagen membrane for guided bone regeneration in mandibular defects in rats. J Periodontol 1998;69(11):1238–46.
34. Brunel G, Piantoni P, Elharar F, et al. Regeneration of rat calvarial defects using a bioabsorbable membrane technique: influence of collagen cross-linking. J Periodontol 1996;67(12):1342–8.
35. Rompen EH, Biewer R, Vanheusden A, et al. The influence of cortical perforations and of space filling with peripheral blood on the kinetics of guided bone generation. A comparative histometric study in the rat. Clin Oral Implants Res 1999;10(2):85–94.
36. Alliot B, Piotrowski B, Marin P, et al. Regeneration procedures in immediate transmucosal implants: an animal study. Int J Oral Maxillofac Implants 1999;14(6):841–8.
37. Benqué E, Zahedi S, Brocard D, et al. Tomodensitometric and histologic evaluation of the combined use of a collagen membrane and a hydroxyapatite spacer for guided bone regeneration: a clinical report. Int J Oral Maxillofac Implants 1999;14(2):258–64.
38. Sanz M, Vignoletti F. Key aspects on the use of bone substitutes for bone regeneration of edentulous ridges. Dent Mater 2015;31(6):640–7.
39. Milinkovic I, Cordaro L. Are there specific indications for the different alveolar bone augmentation procedures for implant placement? A systematic review. Int J Oral Maxillofac Surg 2014;43(5):606–25.
40. Morrow RM, Powell JM, Jameson WS, et al. Tooth-supported complete dentures: description and clinical evaluation of a simplified technique. J Prosthet Dent 1969;22(4):415–24.
41. Feine JS, Carlsson GE, Awad MA, et al. The McGill consensus statement on overdentures. Mandibular two-implant overdentures as first choice standard of care for edentulous patients. Int J Oral Maxillofac Implants 2002;17(4):601–2.
42. Kern JS, Kern T, Wolfart S, et al. A systematic review and meta-analysis of removable and fixed implant-supported prostheses in edentulous jaws: post-loading implant loss. Clin Oral Implants Res 2015;27(2):174–95.
43. Klein MO, Schiegnitz E, Al-Nawas B. Systematic review on success of narrow-diameter dental implants. Int J Oral Maxillofac Implants 2014;29(Suppl):43–54.
44. de Souza RF, Ribeiro AB, Della Vecchia MP, et al. Mini vs. standard implants for mandibular overdentures: a randomized trial. J Dent Res 2015;94(10):1376–84.
45. Bulard RA, Vance JB. Multi-clinic evaluation using mini-dental implants for long-term denture stabilization: a preliminary biometric evaluation. Compend Contin Educ Dent 2005;26(12):892–7.
46. De Kok IJ, Thalji G, Bryington M, et al. Radiographic stents: integrating treatment planning and implant placement. Dent Clin North Am 2014;58(1):181–92.
47. Bornstein MM, Scarfe WC, Vaughn VM, et al. Cone beam computed tomography in implant dentistry: a systematic review focusing on guidelines, indications, and radiation dose risks. Int J Oral Maxillofac Implants 2014;29(Suppl):55–77.
48. Wang Y, Zhang Y, Miron RJ. Health, maintenance, and recovery of soft tissues around implants. Clin Implant Dent Relat Res 2015. [Epub ahead of print].

49. Matthews DC. Prevention and treatment of periodontal diseases in primary care. Evid Based Dent 2014;15(3):68–9.
50. Mishler OP, Shiau HJ. Management of peri-implant disease: a current appraisal. J Evid Based Dent Pract 2014;14(Suppl):53–9.